



A Comprehensive Study on Multimodal Imaging for Early Detection of Ocular Disease

Hira Farooq, M Azam Zia and Muhammad Asif

EasyChair preprints are intended for rapid dissemination of research results and are integrated with the rest of EasyChair.

December 16, 2024

A COMPREHENSIVE STUDY ON MULTIMODEL IMAGING FOR EARLY DETECTION OF OCULAR DISEASE

Hira Farooq¹, Muhammad Azam Zia², Muhammad Asif³

¹Department of Computer Science, University of Agriculture Faisalabad, Faisalabad, Pakistan

²Department of Computer Science, University of Agriculture Faisalabad, Faisalabad, Pakistan

³Department of Computer and Software Engineering, Information Technology University (ITU), Lahore, Pakistan

**email hira350@gmail.com*

Keywords: AMD, Ocular Disease, OCT, Color Fundus, CNN

Abstract

Age-related macular degeneration (ARMD), caused by age-specific retinal damage, is one of the primary causes of blindness. As individuals age, ARMD can impair daily activities and lead to severe vision loss if untreated. Researchers use deep learning (DL) models with OCT and fundus images to diagnose ARMD. This study explores the benefits of combining these imaging modalities with DL approaches, using the Project Macula dataset to develop models with transfer learning. This technique allows the models to adapt to new inputs and learn from diverse data. The study focuses on precision medicine and digital twin concepts, using a dataset of OCT and color fundus images. The attributes were carefully chosen to represent a variety of ARMD cases. A network architecture ensemble was proposed to integrate OCT and fundus data, enhancing prediction accuracy. The dataset was divided into subgroups for testing, validation, and training, with preprocessing to standardize inputs. Experiments compared combined data with individual modalities and other algorithms. Metrics like recall, accuracy, and precision demonstrated the model's effectiveness. This combined approach consistently outperformed individual modalities, highlighting the advantages of data fusion in DL techniques. The findings support automating ARMD screening and advancing computer-aided diagnosis tools, improving patient outcomes.

1 Introduction

AMD is a debilitating eye disease that causes blind spots and vision loss in millions of elderly individuals, significantly impacting their independence and daily living. As the population ages, AMD is becoming an increasing concern, impairing the macula the eye’s specialized area responsible for center vision, making tasks like driving, reading, and face recognition difficult. Beyond visual impairment, AMD also affects mental and emotional well-being, social connections, and overall quality of life, often leading to feelings of sadness, frustration, and isolation. Although there is no cure, early identification and care can be beneficial in preserving vision and slowing the progression of the disease. Preventative measures such as a diet high in omega-3 fatty acids and leafy greens, along with regular eye exams, are essential. Ongoing research offers hope for new treatments and with greater awareness and support, a future where AMD no longer compromises independence and vision may be possible.

AMD was first identified in 1855 by French ophthalmologist Jean-Martin Charcot and has since become one of the main causes of blindness worldwide. The condition damages the macula, a light-sensitive part of the eye, with genetic and lifestyle factors contributing to its progression. Although there is no cure, advances such as anti-VEGF medication and laser treatments have been developed to slow the disease. Despite these strides, AMD remains a significant public health concern, underscoring the need for continued research and innovation [14]

The macula, the area of the retina in charge of central vision, is impacted by AMD, a complicated eye condition. It exists in two forms: dry AMD, which progresses slowly as light-sensitive cells in the macula die and small deposits of fat (drusen) accumulate, and wet AMD, a more severe form that causes rapid vision loss due to abnormal blood vessel growth under the retina. Risk factors include age, genetics, smoking, and high blood pressure. Regular eye exams are crucial for early detection and treatment, which can help slow the disease’s progression. While AMD has no cure, ongoing research seeks to develop better treatments to preserve vision and quality of life [2].

The risk factors for AMD are diverse and can be categorized as personal and environmental. Age, family history, and medical issues including high blood pressure and retinal deposits are examples of personal factors, which increase the risk of AMD. Environmental factors such as lifestyle choices, diet, and exposure to pollutants also play a role in its development. By recognizing these risks, individuals can take preventive actions like regular eye exams, healthy living, and managing systemic health issues. Through such measures, the incidence and

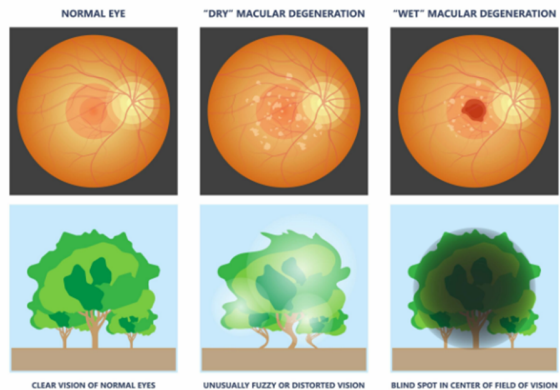


Figure 1: Normal vs Dry vs Wet AMD

impact of AMD can be reduced, helping to preserve vision and improve overall quality of life [10]. Fundus photography and OCT have revolutionized the diagnosis and treatment of AMD by providing unparalleled accuracy. The noninvasive cross-sectional imaging of OCT allows for the early detection of macular abnormalities such as choroidal neovascularization, epithelial detachment of the retinal pigment, and drusen. Combining OCT with fundus photography enhances diagnostic precision, enabling early intervention and treatment before significant vision loss occurs. This advanced imaging approach plays a key role in improving patient outcomes and is expected to remain central to AMD diagnosis and care as research progresses [15].

In 2018, two ophthalmologists created a high-quality dataset of fundus images and OCT scans, featuring normal eyes, "non-neovascular", and "neovascular" AMD. Their dataset, which included 27 normal eyes, "18 non-neovascular" AMD eyes, and "38 neovascular" AMD eyes, was carefully curated with an emphasis on accuracy and reliability. By following strict ethical guidelines and utilizing a public database, their work has significantly advanced AMD diagnosis and treatment. Their openly accessible dataset fosters collaboration and innovation, leading to more precise diagnostic tools, improved treatment plans, and better patient outcomes, offering hope to millions affected by AMD [16]. The AMD, glaucoma, and diabetic retinopathy (DR) are difficult diagnoses because of their complexity and the shortcomings of existing diagnostic techniques, which can be subjective and need numerous imaging modalities. A potential approach is optical coherence tomography angiography (OCTA), which produces fine-grained 3D retinal pictures for quantitative analysis. On the other hand, manual OCTA data analysis requires a lot of time and resources. By merging structural OCT and OCTA data, DL can automate image analysis and diagnose DR, AMD, and glaucoma at the same time.

Improved patient care, focused therapies, and quick and precise diagnosis are all made possible by this integrated approach. Clinicians can transform ophthalmology and improve patient outcomes and survival rates by integrating OCT, OCTA, and DL [17]. According to the World Health Organization, over two billion people worldwide struggle with vision problems, with at least 45 percent of cases being preventable through early detection and treatment. The retina, a tissue at the rear of the eye that is sensitive to light, is essential in diagnosing conditions like AMD, glaucoma, and cataracts, which can lead to blindness if untreated. Imaging techniques like fundus photography and OCT are essential for detecting these diseases. Fundus photography provides 2D images of the retina, while OCT offers cross-sectional views of the retinal layers. However, manually analyzing these images can be time-consuming and challenging. To address this, the development of an automatic CAD system, Fundus-DeepNet, aims to enhance early disease detection using deep learning to process and classify fundus images efficiently. This system could improve telemedicine by providing accurate, timely eye care, especially in underserved areas [1].

1.1 Motivation

It is very important for eye care to find faster and more accurate ways to diagnose and treat retinal diseases. To quickly and accurately find and treat problems, eye doctors need better tools. Using advanced electronic records and machine learning techniques along with retinal picture screening is a strong suggestion. Improving patient results, lowering healthcare costs, and making better medical decisions are all possible by automating picture analysis. As a result of this paper, this new way of doing things will become the new standard in eye care.

1.2 Problem Statement

The use of single imaging modalities, such as OCT or color fundus images, limits diagnostic accuracy, necessitating a multimodal approach to combine both for enhanced precision in diagnosing AMD.

1.3 Objectives

- Created a CNN to detect AMD early.
- Combined two types of eye images, OCT and Fundus, to increase the accuracy of detection.
- Used a dataset from Kaggle to train and test the model effectively.
- Showed that using both types of images together helps in detecting AMD more accurately.

2 REVIEW OF LITERATURE

[11] explained that AMD was a common problem with the retina that hurt people’s eyesight. While traditional diagnostic systems used color fundus camera pictures, DL had shown promise, predicting AMD severity with nearly 90 percent accuracy and doing better than human judges. Unfortunately, fundus camera pictures alone had their limits because they were flat. OCT scans were commonly used in clinics because they gave invaluable 3D structure information. Diabetes-related macular edema and AMD could be accurately diagnosed by DL models using OCT pictures. Although both fundus and OCT pictures are commonly used in clinical settings, the diagnostic value of using them together in ML literature has not been fully explored. The purpose of this experiment was to find out if measuring the fundus in addition to OCT images could help tell the difference between people with normal vision and those with AMD.

[7] imposed that the macula situated at the posterior of the eye was crucial for central visual acuity and high-resolution color image perception. AMD, classified into four stages, could lead to substantial central vision loss and blindness in advanced stages. Early detection was vital, and scrutinizing fundus images was a basic examination for diagnosis. AMD’s etiology involved factors like heredity, chronic photo destruction effects, and dietary disorders, often associated with drusen accumulation. Automated retinal image analysis had evolved from traditional algorithms to ML techniques and, more recently, DL. DL, particularly CNNs, had offered improved performance in various medical image analysis tasks, including diagnosing DR and identifying retinal detachment. The suggested technique effectively used DL to identify fundus pictures damaged by AMD, eliminating the need for human attribute estimation and evaluation.

[9] addressed that AMD is a state that is defined by the progressive loss of central vision due to age-related damage to the macula. Projections suggest a significant rise in its prevalence in the coming years, highlighting the urgent need for improved diagnostic approaches. Researchers have turned to AI and DL techniques to automate screening processes, particularly in regions with large populations or limited healthcare resources. In the realm of AI, DL, a subset known for its prowess in image analysis, shows promise for AMD diagnosis. Traditional CNNs have been the primary choice for this task, but newer transformer-based models, originally designed for sequential data processing tasks like natural language, offer intriguing possibilities for AMD classification. These models leverage self-attention mechanisms to capture complex relationships within retinal images. While CNNs have been

the go-to architecture for AMD diagnosis, researchers are delving into newer approaches such as EfficientNet, and ResnetRS to potentially enhance performance. Furthermore, ensemble methods and data augmentation techniques are being explored to boost model accuracy. The quest to enhance AMD diagnosis through advanced AI and DL methodologies represents a critical frontier in vision research. By harnessing cutting-edge technologies and continuously advancing innovation, researchers aim to develop more accurate and efficient tools for detecting and managing this debilitating disease.

[3] defined ocular diseases leading to blindness have become more prevalent. These diseases affect various parts of the eye and include conditions like cataracts, nearsightedness, trachoma, AMD, and diabetic retinopathy. These contribute significantly to global visual impairment, with around 1 billion cases of untreated or preventable vision deficiencies reported. AMD, especially, affects older adults, causing gradual central vision disturbances. Timely identification is crucial for effective management, with early intervention associated with a high success rate in recovery. ML techniques, particularly DL, have transformed early AMD detection, offering significant advantages over manual methods. These technologies, coupled with digital ocular images and artificial intelligence, enhance diagnostic capabilities in ophthalmology. Researchers are focusing on improving AMD detection using DL methods like CNNs and long short-term memory (LSTM) networks. This paper presents a novel system integrating CNN and LSTM networks for automated AMD detection from fundus photographs. The dynamic fusion of these networks significantly improves AMD classification, outperforming 13 pretrained DL models. The main contributions include improved AMD classification, rigorous benchmarking, and effective utilization of preprocessing techniques and diverse datasets, enhancing the proposed framework's real-world effectiveness.

3 METHODOLOGY

The study utilized advanced imaging tools like spectral domain or swept-source OCT and a digital fundus camera to obtain detailed cross-sections and 2D images of the retina. Mydriatic eye drops were administered to enhance image quality by dilating the pupils. The researchers also examined patients' medical records to gather demographic and health information. These imaging techniques allowed for the detection of retinal changes such as macular thinning, fluid accumulation, and pigment epithelium separation. By comparing OCT and fundus images over time, the study provided insights into the progression of macular degeneration and the effectiveness of treatments. Statistical analyses were

then conducted to correlate these findings with the severity of the disease.

3.1 Data Collection

Data from an OCT and Fundus camera will be taken from 384 people, 269 of whom have been identified with ARMD and 115 of whom are thought to be healthy. Along with information about the center part of the retina within a 5mm diameter boundary, the collection 39 will include characteristics like age. The "Joint Shantou International Eye Centre (JSIEC) in Shantou city, Guangdong province, China", is where all 1000 fundus pictures from 39 groups were gathered. A smaller group of the "209,494 fundus images" that our DL system uses for learning, validation, and measurement. The original owners of these pictures are still JSIEC. In order to help with eye research, this collection includes information about ARMD patterns, age-related trends, and the link between retinal health and the characteristics given [6].

3.2 Model Evaluation

In order to guarantee the accuracy and dependability of forecasting models, model assessment is necessary stage in the development process. In this step, a different dataset that wasn't utilized for training referred to as the test or validation set is accustomed to test the model. Evaluating the model's predictive power in relation to actual outcomes is the aim. Model assessment makes use of methods such as confusion matrices and cross validation to guarantee thorough and trustworthy research. While confusion matrices offer a comprehensive breakdown of true positives, false positives, true negatives, and false negatives, cross-validation involves clustering the data, testing the prototype on some, and training it on others. Through comprehensive assessment of predictive models, scientists may create reliable models that yield precise predictions in practical applications.

3.3 Google Colab

With Google Colab, users can develop and execute Python code straight from a web browser, which is also known as Google Collaboratory. It's especially helpful for machine learning, data analysis, and teaching. Free access to GPUs and TPUs is available through Colab. These resources help speed up the processing of big datasets and training complex models. With Jupyter notebooks, users can easily record and share their findings and results by creating, sharing, and working together on them. Numerous tools, such as NumPy, Pandas, Matplotlib, Seaborn, Scikit-learn, and PyTorch, are already in-




Figure 2: Flow Diagram

stalled on the platform, so users can start writing code right away without having to go through complicated setup steps. Additionally, Google Colab works well with Google Drive, as shown in Figure 3.2, which makes it easy to keep and handle notebooks and datasets. These features easy access, powerful computing power, and a user-friendly interface make Google Colab a very useful tool for workers, students, and academics in many fields.

3.4 Model Innovation

The code begins the training process for both datasets (1000images and OCTID) by calling the function `train_model` with these exact inputs. `ImageDataGenerator` instances are probably used to preprocess and add to the training data inside the `train_model` method. This makes sure that the model sees a variety of cases and learns strong features. Using `ImageDataGenerator` instances that are set up for validation to process the validation data separately lets you keep an eye on the functionality of the model and makes sure that the training data is not overfitted. In that manner of training makes it easier to build a neural network model that can correctly sort images from the datasets that are given. Eventually, this will allow the model to work well with new pictures that it hasn't seen before in real life. Using these parameters to call the `train_model` function sets the stage in order to train a model of neural networks on picture data utilizing two separate datasets and making sure it works well by carefully validating and setting the parameters.

Initial, the images were split into two groups: a full training set, which included images used to teach a CNN to recognize the complex patterns and features of AMD; and a separate set of normal images,

which were added to the training set to provide a solid basis for comparison. Next, a separate set of test pictures that needed to be classified were used for feature extraction. Methods like convolutional layers and pooling were used to simplify the most important features of each image. Furthermore, the normal picture features from the training set were extracted in the same way, making a reference standard. The highlighted parts of both the test and regular pictures were then compared using the Local Outer Factor algorithm, a complex way to find patterns and links. Utilizing the power of CNN and feature extraction methods, this comparison made it possible to accurately classify each test picture as either normal or showing signs of AMD.

4 RESULTS AND DISCUSSION

4.1 Overview

A lot of older people in industrialized countries lose their central vision because of AMD. By 2040, 288 million people will have this condition. This shows how important accurate statistical data is for planning healthcare and coming up with ways to keep people from getting sick. There isn't a single agreed upon way to identify and grade AMD, especially in its early and middle stages, even though many population-based studies have shed light on how common it is. CFP is a big part of traditional grading, but more and more people are using multimodal imaging methods like "SD-OCT", "infra-red (IR)", and "fundus autofluorescence (FAF)", which are better at diagnosing. This change is meant to make it easier to compare studies and improve how AMD is staged. The Coimbra Eye Study (CES) in Portugal has helped us figure out how common AMD is and what factors put people at risk for getting it. An updated follow-up study on the seaside community of Mira compared standard CFP staging for AMD with a multimodal method that used "CFP", "SD-OCT", "IR", and "FAF". The goal of this study is to find out how multimodal imaging changes epidemiological statistics and what that means for reporting AMD cases [4].

4.2 Multi-Input Model

TensorFlow's Keras API is being used to define two input layers. CF and OCT images are the two distinct input data streams that are represented by the `oct_input` and `cf_input` layers. All input layers support images of the form $(img_size, img_size, 3)$, where 3 denotes the RGB color channels and `img_size` is the image's dimensions (e.g., 224x224 pixels). These layers act as stand-ins for the input data that the neural network will receive. Through the use of two distinct inputs, as shown in Figure

Accuracy	Loss	Val-accuracy	Val-loss
0.4137	1.1706	0.1799	2.8965
0.5928	0.4312	0.1654	10.7939
0.8677	0.4024	0.1583	53.5317
0.8571	0.3193	0.2075	34.8661
0.8919	0.3016	0.1942	4.0557
0.9107	0.2303	0.1575	2.6312
0.9322	0.1838	0.2014	2.4686
0.9422	0.1775	0.1780	2.4640
0.9670	0.1223	0.1890	2.4928
0.9543	0.1409	0.1727	2.2967

Figure 3: Accuracy Table

4.6, the model is able to process and learn from the OCT and Color Fundus datasets simultaneously. This could allow the model to perform multi-modal analysis, which would enhance its capacity to identify and categorize retinal conditions such as AMD by utilizing the complementary information provided by both forms of imaging [5].

4.2.1 Combine OCT and CF Branch

The Keras API is being used to create a neural network model. The layers of tf.keras, the two input tensors, oct_x and cf_x, are merged into a single tensor called combined_x using the concatenate () layer. The model may incorporate information from both inputs thanks to this concatenation, which is carried out along the designated axis. Then, in order to assist add non-linearity and learn complicated patterns, the merged tensor is with a "ReLU activation" function and a completely linked layer with 128 units, as shown in Figure 4.10. Five more dense units with a softmax activation function are added, which is commonly employed for classification tasks to probability of each of the five classes' outputs, produces the model's final output. Then, the model is defined with the ultimate result being the calculated output and the inputs being oct_input and cf_input.

4.2.2 Comparative Analysis

Multi-model Imaging Imaging methods are very important for diagnosing and treating many diseases. However, each one has its own limits and information that may not be shared with others. Digital Subtraction Angiography (DSA) has been the best way to look at vascular problems for a long time because it gives two-dimensional pictures even though it is invasive. Computed Tomography Angiography (CTA), on the other hand, is less invasive and can quickly produce cross-sectional pictures with high spatial resolution. However, it has

poor soft tissue resolution and requires a large amount of radiation. MRI and Magnetic Resonance Angiography (MRA) are less common in vascular surgery because they take longer to scan and cost more. However, they can produce high-resolution images of soft tissues without any penetration limits, though the software we have now has trouble with three-dimensional reconstructions. Multimodal Imaging (MMI) takes advantage of the difficulties of single-modality tests by using two or more imaging methods together in a single exam to produce pictures with a wide range of information. Using MMI in combinations like CT and PET or PET and SPECT can help us understand both how things work and how they are put together. MMI is useful for both diagnosing and treating problems. It is especially helpful in vascular surgery where image fusion helps guide arterial treatments. When IF is done, three-dimensional artery 69 reconstructions are put on top of live fluoroscopy. Models from preoperative CTA, MRA, or peri procedural contrast-enhanced Cone-Beam CT (CBCT) are used. Typically, this is done in a hybrid operating room (HOR), a special room that lets doctors diagnose and treat patients in the same space. This keeps patients from having to move around and saves valuable time in situations. The goal of this study is to look into the newest ways that MMI can be used to diagnose and treat urgent circulatory problems [8].

4.2.3 OCT Model

AMD High-resolution inside the body by finding new anatomical signs, OCT imaging has made a big difference in studies into neovascular AMD. More and more patients needing OCT scans and more people being scanned at once create problems that can be solved with automatic tools for thorough analysis and segmentation. While parameters like central subfield thickness (CST) are used in clinical studies, other OCT parameters have become more popular because of their flaws, such as segmentation errors and a lack of specific information. Deep learning progress has made it possible to automatically and accurately evaluate traits like intraretinal fluid (IRF) and subretinal fluid (SRF), which could have useful clinical uses. De Fauw et al. created an AI system that can diagnose and target retinal diseases. The segmentation network was used on OCT scans of patients starting anti-VEGF treatment, which gave researchers more useful information for further AMD study [12].

4.2.4 Color Fundus Model

Eye diseases are an issue for health around the world. They are becoming more common, which is hard for medical systems and lowers the quality of life for people. Ocular diseases like AMD, cataracts,

glaucoma, and diabetes-related eye diseases need to be diagnosed quickly and correctly in order to improve treatment results and lessen the effects of the disease. Even though color fundus photos are used a lot in ophthalmology, it is still hard to diagnose these conditions because symptoms can overlap, data isn't always fair, image quality can vary, and a person could have more than one disease at the same time. New technologies like AI and ML are becoming useful for dealing with these issues because they can look at big datasets, find small patterns, and make correct predictions. CNN is a type of DL model that is very good at classifying pictures and can be used to look at medical images, such as color fundus shots. For instance, Zhang et al. made a model that combines a cycle generative adversarial network (CycleGAN) with a CNN to find eye diseases and localize tumors with little training data. This model works very well across a number of datasets. This kind of AI could help doctors make 70 better decisions and make eye care more efficient by automatically finding diseases and making diagnoses more accurate. But more study needs to be done to make these models better so they can be used in more clinical settings and to see how cost-effective and useful they are in current healthcare systems [13].

5 SUMMARY

AMD is a progressive eye disease that significantly impacts the quality of life for older adults by causing vision loss and blind spots. It disrupts daily activities like reading, driving, and recognizing faces, while also affecting emotional well-being, often leading to isolation and anxiety. Although early diagnosis and treatment can slow its progression, there is currently no cure, emphasizing the importance of regular eye checkups and healthy lifestyles.

Advancements in retinal imaging and machine learning are paving the way for improved diagnostic tools. This thesis focuses on using deep learning techniques to enhance AMD detection by integrating OCT and fundus images. The proposed method combines multiple data sources, providing more accurate diagnoses compared to single-modality approaches. By automating image analysis, this strategy seeks to facilitate speedier clinical judgments, lower healthcare expenses, and enhance patient outcomes.

The study pioneers a robust system that leverages CNNs for accurate AMD classification. By continuously learning and refining its models, the system promises earlier detection with fewer invasive tests. This cutting-edge AI-driven approach could revolutionize ophthalmology, empowering doctors with superior diagnostic tools and offering patients better care worldwide. This innovative research strives to set new standards in eye care.

References

- [1] Shumoos Al-Fahdawi, Alaa Al-Waisy, Diyar Zeebaree, Rami Qahwaji, Hayder Kadhim, Mazin Mohammed, Jan Nedoma, Radek Martinek, and Muhammet Deveci. Fundus-deepnet: Multi-label deep learning classification system for enhanced detection of multiple ocular diseases through data fusion of fundus images. *Information Fusion*, 102, 09 2023.
- [2] Abdulaziz Alghamdi, Abeer Mutairi, Afaf Alanazi, Asrar Almutairi, Mei Alfaqiri, Sultan Al-Ruwaili, Faisal Al-Ghamdi, Sarah Bukhari, Mohammed Alrefai, Lina Aljohani, Sarah Ali, and Sarah Bukhamsin. Age-related macular degeneration: Simple review. *Journal of Pharmaceutical Research International*, pages 35–40, 07 2021.
- [3] Md. Aiyub Ali, Md. Shakhawat Hossain, Md. Kawsar Hossain, Subhadra Soumi Sikder, Sharun Akter Khushbu, and Mirajul Islam. Amdnet23: Hybrid cnn-lstm deep learning approach with enhanced preprocessing for age-related macular degeneration (amd) detection. *Intelligent Systems with Applications*, 21:200334, 2024.
- [4] Rashid Amin, Adeel Ahmed, Syed Hasan, and Habib Akbar. Multiple eye disease detection using deep learning. *Foundation University Journal of Engineering and Applied Sciences (HEC Recognized Y Category, ISSN 2706-7351)*, 3, 01 2023.
- [5] Alessandro Arrigo, Emanuela Aragona, Maurizio Parodi, and Francesco Bandello. Quantitative approaches in multimodal fundus imaging: State of the art and future perspectives. *Progress in Retinal and Eye Research*, 92:101111, 08 2022.
- [6] Cen, Ji Ling-Ping, Lin Jie, Ju Jian-Wei, Lin Si-Tong, Li Hong-Jie, Wang Tai-Ping, Yang Yun, Zhang Jian-Feng, Luo Xiaoling, Huang Li, Zhang Chukai, Huang Guihua, Ng Yuqiang, Chen Tsz Kin, Chen Haoyu, Pang Weiqi, Zhang Chi Pui, and Mingzhi. Automatic detection of 39 fundus diseases and conditions in retinal photographs using deep neural networks. *Nature Communications*, 12, 2021.
- [7] Rivu Chakraborty and Ankita Pramanik. Dnn-based prediction model for detection of age-related macular degeneration from color fundus images. *Medical Biological Engineering Computing*, 60, 03 2022.
- [8] Elda Chiara Colacchio, Mariagiovanna BERTON, Francesco Squizzato, Mirko Menegolo, Michele Piazza, Franco Grego, and

- Michele Antonello. The role of multimodal imaging in emergency vascular conditions: The journey from diagnosis to hybrid operating rooms. *Seminars in Vascular Surgery*, 36, 04 2023.
- [9] César Domínguez, Jónathan Heras, Eloy Mata, Vico Pascual, Didac Royo, and Miguel Ángel Zapata. Binary and multi-class automated detection of age-related macular degeneration using convolutional- and transformer-based architectures. *Computer Methods and Programs in Biomedicine*, 229:107302, 2023.
- [10] Mahdi Gheorghe and Musat. Age-related macular degeneration. *MEDLINE*, 2015 Apr-Jun.
- [11] Cecilia Lee, Doug Baughman, and Aaron Lee. Deep learning is effective for classifying normal versus age-related macular degeneration optical coherence tomography images. *Ophthalmology Retina*, 2, 02 2017.
- [12] Thomas Schlegl, Sebastian M Waldstein, Hrvoje Bogunovic, Franz Endstraßer, Amir Sadeghipour, Ana-Maria Philip, Dominika Podkowinski, Bianca S Gerendas, Georg Langs, and Ursula Schmidt-Erfurth. Fully automated detection and quantification of macular fluid in oct using deep learning. *Ophthalmology*, 125(4):549–558, April 2018.
- [13] Jing-Zhe Wang, Nan-Han Lu, Wei-Chang Du, Kuo-Ying Liu, Shih-Yen Hsu, Chi-Yuan Wang, Yun-Ju Chen, Li-Ching Chang, Wen-Hung Twan, Tai-Been Chen, and Yung-Hui Huang. Classification of color fundus photographs using fusion extracted features and customized cnn models. *Healthcare*, 11(15), 2023.
- [14] JO-HSUAN WU, TAKASHI NISHIDA, ROBERT N. WEINREB, and JOU-WEI LIN. Performances of machine learning in detecting glaucoma using fundus and retinal optical coherence tomography images: A meta-analysis. *Elsevier*, 237, 2022.
- [15] Jason Yim, Reena Chopra, Terry Spitz, Jim Winkens, Annette Obika, Christopher Kelly, Harry Askham, Marko Lukic, Josef Huemer, Katrin Fasler, Gabriella Moraes, Clemens Meyer, Marc Wilson, Jonathan Dixon, Cian Hughes, Geraint Rees, Peng Khaw, Alan Karthikesalingam, Dominic King, and Jeffrey Fauw. Predicting conversion to wet age-related macular degeneration using deep learning. *Nature Medicine*, 26:1–8, 06 2020.
- [16] Tae Keun Yoo, Joon Yul Choi, Jeong Seo, Ramasubramanian Bhoopalan, Sundaramoorthy Selvaperumal, and Deok Won Kim. The possibility of the combination of oct and fundus images for improving the diagnostic accuracy of deep learning for age-related macular degeneration: a preliminary experiment. *Medical Biological Engineering Computing*, 57, 10 2018.
- [17] Pengxiao Zang, Tristan Hormel, Thomas Hwang, Steven Bailey, David Huang, and Yali Jia. Deep-learning-aided diagnosis of dr, amd, and glaucoma based on structural and angiographic optical coherence tomography. *Ophthalmology Science*, 3:100245, 11 2022.